

Atrial Septal Defect Guideline

What the Nurse Caring for a Patient with Congenital Heart Disease Needs to Know

Sandra McGill-Lane, MSN, RN, FNP, CCRN
Clinical Nurse Specialist, Pediatric Cardiac Intensive Care Unit
Morgan Stanley's Children's Hospital of NY-Presbyterian

Meghan Cusick, MSN, RN, NP-C
Cardiology Preoperative Clinic Nurse Practitioner
Boston Children's Hospital

Erin Burke, MSN, RN, PNP
Cardiology Preoperative Clinic Nurse Practitioner
Boston Children's Hospital

Catherine Murphy, BSN, RN.
Staff Nurse, Cardiac Critical Care Unit. Labatt Family Heart Centre
Hospital for Sick Children, Toronto

Cecilia St. George-Hyslop, M Ed, RN, BA Gen., CNCCPC
Advanced Nursing Practice Educator, Cardiac Critical Care Unit, Labatt Family Heart Centre
Hospital for Sick Children, Toronto

Introduction

Atrial septal defects (ASDs) are holes in the atrial septum and account for 7-10% of all congenital heart defects (CHD), 3rd most common defect. There is a higher incidence in females. (Kazmouz, 2013). ASDs are also part of many of the more complex forms of congenital heart disease. Associated anomalies include pulmonary stenosis (PS), tricuspid or mitral valve abnormalities, and partial anomalous pulmonary venous drainage (PAPVD).

Embryology

- Normal Development
 - Atria begin to divide about the fifth week of life
 - Division involves the septum primum, septum secundum, and atrioventricular (AV) canal septum
 - ASDs result from failure of the atria to divide normally
 - Simple defects
 - Complex defects associated with a constellation of other abnormalities in heart structures
- Septum Primum
 - First septum to appear
 - Crescent shaped structure
 - Forms caudally toward the endocardial cushion
 - Ostium primum
 - Septum primum and the endocardial cushion meet and fuse

- Separate right and left atrium
 - Septum Secundum
 - Second orifice
 - Arises on the right atrial side of the septum primum
 - Fossa ovalis formed by the septum secundum covering the ostium secundum
 - In fetus the atria not completely divided by septum secundum
 - Foramen ovalae formed by the residual oval opening
 - In fetus
 - Opening patent due to the differential pressure between left and right atrium
 - Right atrial pressure higher than left atrial pressure
 - Foramen maintains open
 - Allowing for right to left flow of blood
 - After birth
 - Right atrial pressure drops as the lungs expand and systemic vascular resistance rises
 - Pressure change causes the septum primum to be held against the septum secundum
 - Result in closing the intra-atrial shunt
- Ostium secundum
 - Second orifice in septum primum
 - Covered by septum secundum
 - Arises on right atrial side of septum primum
 - Septum secundum grows caudally covers ostium secundum
 - Forms the fossa ovalis
 - In fetus
 - Does not completely divide atria
 - Leaves an oval orifice
 - Foramen ovalae
 - Covered, but not yet sealed, on left side by flexible flap of septum primum
- Foramen ovalae
 - After birth
 - Septum primum and septum secundum fuse
 - Forms an intact atrial septum
 - Occurs in about 70% of population
 - Remains open
 - Patent foramen ovalae (PFO)
 - Septae do not fuse
 - May be covered but not sealed – “probe patent” PFO
 - Occurs in about 30% of population
 - May reopen
 - Reversal of interatrial pressures
 - May occur with pulmonary hypertension (PH)

- Persistent open atrial communication = true ASD

Anatomy

- ASDs classified by location – 5 main types (See illustration below)
 - Patent foramen ovalae
 - Sinus venosus ASD (Number 3 in illustration below)
 - Secundum ASD (Number 2 in illustration below)
 - Primum ASD (Number 1 in illustration below)
 - Coronary Sinus ASD (Number 4 in illustration below)

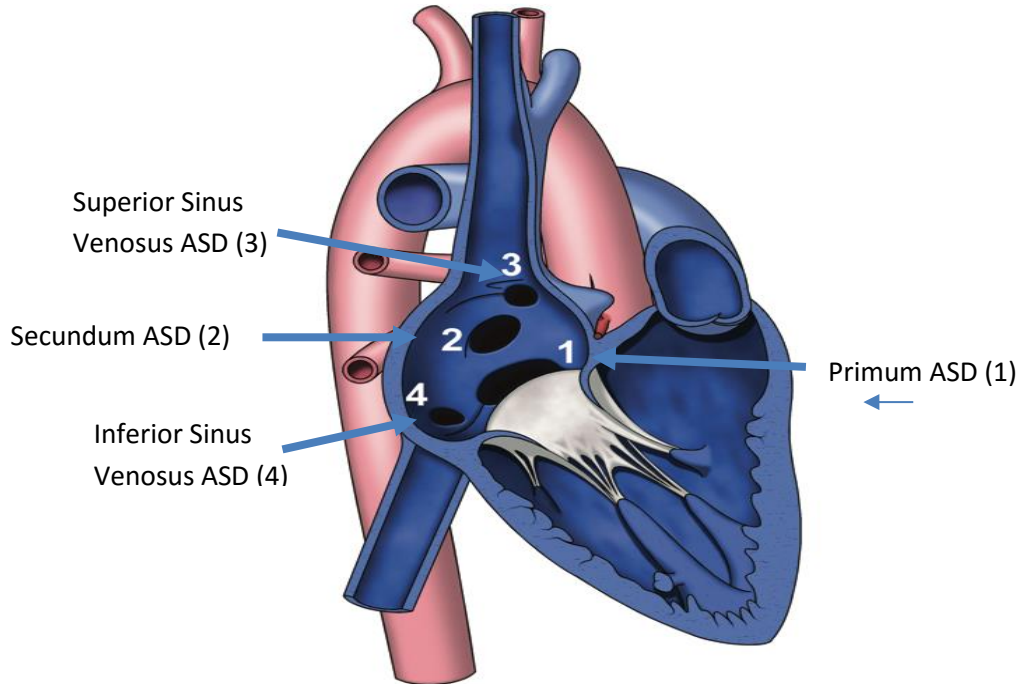


Illustration reprinted from PedHeart Resource. www.HeartPassport.com.
 © Scientific Software Solutions, 2016. All rights reserved.

- Sinus Venosus ASD
 - 10% of ASDs
 - Outside area of fossa ovalis
 - High or low in atrial septum, close to the mouth of the superior vena cava (SVC) or inferior vena cava
 - High location
 - Most common
 - Anomalous communication between one or more of the right pulmonary veins (usually the right upper pulmonary vein) and cardiac end of the SVC
 - Low location - Posterior-inferior atrial wall just above the IVC to RA junction.
- Patent Foreman Ovalae (PFO)
 - 20% of ASDs

- Foramen secundum without closure and fusion of primum and secundum septae
- Persistent communication between atria = true ASD
- Secundum ASD
 - 50-70% of ASDs
 - Isolated defect
 - Twice as common in females
 - Simple mid-septum ASD
 - Secundum ASD, same hole as PFO but hole is not covered by septum secundum
 - Hole too big or septum secundum insufficient
 - Results from arrested growth of secundum septum or excessive absorption of primum septum
 - Typically located within fossa ovalis
 - Multiple defects if floor of fossa ovalis is fenestrated
 - Defects vary greatly in size
 - Less than 3 mm to greater than 20 mm
 - Often large defects
 - May be associated with, or continuous with other ASDs, such as a sinus venosus defect or a primum defect
 - May have functional mitral valve prolapse
 - Related to changes in left ventricular (LV) geometry
 - Associated with right ventricular (RV) volume overload
- Primum ASD
 - 30% of ASDs
 - Low in the atrial septum
 - One of several variants of atrioventricular septal defect (AVSD)/common AV canal defects (See Pediatric Neonatal Defect Guidelines on Atrioventricular Septal Defect)
 - Failure of septum primum to fuse with endocardial cushions
 - Inter-atrial communication between the anterior-inferior margin of fossa ovalis and AV valves
 - Characteristics
 - Common AV orifice with two distinct AV valve annuli
 - Completed by valve tissue adhering to the crest of the ventricular septum
 - AV tissue occludes the space that accounts for the ventricular septal defect (VSD) component in the complete form of the malformation
 - AV valves almost always abnormal
 - Most commonly a cleft in anterior mitral valve leaflet
 - Associated with Down's Syndrome (Trisomy 21)
- Coronary Sinus ASD
 - 1% of ASDs
 - Uncommon
 - Located at mouth of the coronary sinus

- Results from partial or complete unroofing of tissue separating coronary sinus from LA
- Allows a shunt through defect and coronary sinus orifice

Physiology

- Size of the shunt determines clinical symptoms
 - Range from asymptomatic or mild symptoms to CHF, and/or pulmonary vascular disease with PH
- Direction of shunt flow
 - Driven by ventricular compliance and/or AV valve function
 - Not determined by size of defect
 - Even with small defect that may be considered to be restrictive
 - Shunt flow still dependent upon ventricular compliance and PVR
 - At birth
 - Shunting may be limited
 - High PVR that exists in utero
 - Associated RVH
 - Normal changes
 - Decrease in PVR
 - Increase in LV muscle mass
 - Left-to-right shunt
 - May not develop until several months
 - Due to progressive decrease in PVR
 - Increase in LV muscle mass
 - Followed by left to right shunting at atrial level
 - Results in significant ASD shunting with ASD
 - Right-to-left shunt (See Pediatric Neonatal Defect Guidelines for Tricuspid Valve, Pulmonary Valve, Pulmonary Atresia, and Tricuspid Atresia)
 - Increase pressure on right side
 - At birth
 - Lesions with increased right sided pressure
 - Include tricuspid atresia (TA), pulmonary stenosis (PS), pulmonary atresia (PA)
 - After birth (See Adult and Pediatric Neonatal Guidelines on Pulmonary Hypertension and Eisenmenger Syndrome)
 - Increased PVR
 - RVH
 - Symptoms
 - Infancy and Childhood
 - Usually symptom free
 - May have frequent respiratory tract infections
 - May see
 - Fatigue
 - Shortness of breath
 - Exercise intolerance
 - Palpitations

- Adults
 - Exercise intolerance
 - Atrial tachyarrhythmias
 - Atrial flutter/fibrillation
 - 1st degree AV block
 - Palpitations
 - RV dysfunction
 - PH

Pre-procedural Investigation

- Physical assessment
 - Systolic ejection murmurs heard at left sternal border
 - May be wide fixed splitting of S2 heart sound
 - May be a mid-diastolic murmur at the lower left sternal border
- Diagnostic studies
 - Required for both surgical and device closure
 - Delineate size, location, surrounding tissue, PVR, and direction of pulmonary/systemic shunt (QP:QS) if present
- Diagnostic tests – abnormal changes
 - Electrocardiography (ECG)
 - Right axis deviation (RAD) on EKG due to RV enlargement from increased volume
 - Right ventricular hypertrophy (RVH) from right ventricular overload
 - Chest X-rays
 - Mild to moderate cardiac enlargement
 - Usually occurs with congestive heart failure (CHF)
 - Rarely occurs in early childhood
 - Identifies problems in mid adulthood
 - Consistent with presence of large left-to-right shunt
 - Echocardiography and Doppler studies
 - Defines size, location, and direction of shunt
 - Determine degree of pulmonary:systemic shunt (QP:QS)

Qp:Qs	Shunt Effect
1.0	No shunt
1.0 - 1.5	Small restrictive shunt
1.5 – 2.3	Moderate shunt
> 2.3	Large unrestrictive shunt

- Evaluates defect for closure
 - Device vs surgical
 - Size of defect - greater than 5mm
 - Rims of surrounding atrial tissue
- Magnetic resonance imaging (MRI)
 - Less frequently used
- Cardiac catheterization

- Used for device closure and/or unclearly defined ASDs
- Evaluate pulmonary vascular bed
 - PH
 - Response to pulmonary vascular dilators
 - Inhaled – nitric oxide
 - Medications
- Evaluate shunt
 - Direction
 - Significance
 - Increase (Step-up) in oxygen saturation in RA
 - Left-to-right shunt
 - Increase of 5% or more in oxygen saturation in RA from SVC indicates oxygenated blood moving from LA to RA or from LV to RA through an ASD
 - No change in oxygen saturation
 - No shunt
 - May indicate pulmonary vascular disease
 - Requires further evaluation of pulmonary pressures, LAP, LV end diastolic pressure (LVEDP)
 - Requires evaluation of reactivity of pulmonary vascular bed

Management

- Infants
 - Medical management for symptoms of CHF
 - Digoxin
 - Diuretics
- Children
 - Assessed and followed for spontaneous closure
 - Approximately 80% of secundum ASDs 3-8mm in diameter close by 18 months of age
 - Less likely to close after 2 years of age
- Adult
 - Symptomatic patients require complete hemodynamic evaluation
 - Intervention in adulthood
 - Significant impact on quality of life
 - Decreases mortality in > 35 year old population
- Indications for Closure
 - All sinus venosus and ostium primum defects
 - Secundum defects
 - Four years of age or older
 - ASD > 8mm
 - Left to right shunt and PVR < 2/3 of SVR
 - Hemodynamically significant shunt

- Enlargement of right heart structures
 - Evidence of RVH
 - Irrespective of symptoms.
 - Qp: Qs \geq 1.5:1 or greater
 - Borderline shunts
 - Flow ratios of 1-1.5: 1
 - In conjunction with RVH
 - Contraindications to Closure
 - PH not absolute contraindication
 - Recommendations of American and European Practice Guidelines
 - May be closed if:
 - PVR lower than two-thirds of SVR at baseline or after pulmonary vasodilator acute challenge
 - Targeted pretreatment course with evidence of a pulmonary-to-systemic flow ratio greater than 1.5
 - Advanced PH
 - Right to left shunting across the ASD
 - Calculated PVR $>$ 8 Woods Units
 - Resting interatrial right-to left shunt
 - Rarely seen
 - Seen in Eisenmenger syndrome
 - Surgical intervention contraindicated when PVR \geq 10 Woods Units \times m²
 - Defect serves as a decompressing route for blood flow (pop-off valve)
 - Includes severe obstructive or
 - Restrictive right or left heart lesions
 - Sepsis
 - Contraindications to device closure

ASD Closure Procedures: Surgical/Device

- Closure indicated (See above discussion under Management)
 - CHF present
 - Defect not spontaneously closed by 2-4 years of age
- Two treatment options – surgical or device
 - Choice depends on:
 - Location and size of defect
 - Patient size
 - Hemodynamic stability
 - Institutional preference
 - Main goal: to decrease likelihood of developing PH
 - Surgical procedure (See Pediatric Neonatal Guidelines on Postoperative Care, Hemodynamic Monitoring, Arrhythmia Management)
 - Safe, effective
 - Defects
 - Sinus venosus
 - Primum
 - Coronary sinus

predominant volume overload and later pressure overload on the right heart leads to chamber enlargement with diastolic septal shift towards the LV and adverse interventricular interaction resulting in decreased LV compliance. These changes result in decreased LV diastolic filling, increased Qp: Qs flow ratio through the defect, and diminished systemic output.

- A longstanding shunt results in impaired right atrial reservoir and pump functions, RV dilatation, myocardial cell hypertrophy and fibrosis, and cellular injury. This manifests as an increased serum concentrations of cardiac troponin. The pulmonary vascular bed remodels with myointimal cell proliferation, increased medial smooth muscle, and increased collagen leading to arteriolar narrowing and PH.
- Mild increase in pulmonary artery pressure is common in young patients with a large atrial septal defect, but a few (6–19 %), mostly female patients, will develop pulmonary vascular disease over time.

Long Term Problems/Complications

- Unrepaired ASD (See both Adult and Pediatric Neonatal Guidelines for Arrhythmia Management, Pulmonary Hypertension, and Eisenmenger Syndrome)
 - Increased pulmonary blood flow
 - Causes pulmonary over circulation
 - May result in pulmonary vascular disease (PH)
 - Hemodynamically insignificant and closure is not recommended
 - Follow for changes in hemodynamic status
 - Dilated RA
 - PH
 - Dilated pulmonary arteries
 - Exertional dyspnea (exercise intolerance)
 - Symptoms of CHF
 - Stroke
 - Late complications of unrepaired adult secundum ASDs
 - Atrial arrhythmias due to cardiac remodeling secondary longstanding hemodynamic overload
 - PH
- Repaired ASD
 - Hemodynamic response
 - Reduction in RA and RV size
 - Most of decrease occurs immediately
 - Further remodeling over following 1–2 years
 - Factors associated with normalization of RV size
 - Younger age at closure
 - Degree of RA enlargement before repair
 - Improvement in symptoms
 - Increase in somatic growth in young children
 - Short term results
 - Outcomes good
 - Both for device and surgical repair
 - Safe

- Residual shunts rare
- Surgical complications (See Pediatric Neonatal Guidelines on Postoperative Care and Arrhythmias)
 - 1st degree AV block
 - May require permanent pacemakers for bradycardia
 - Atrial arrhythmias
 - Atrial fibrillation/atrial flutter
 - Supraventricular tachycardia (SVT)
 - Junctional rhythm
 - Pericardial effusions
 - Infrequent complications: bleeding, transient neurologic events, pneumonia and atelectasis
- Device complications
 - Minor complications
 - Atrial arrhythmias
 - Vascular complications
 - Transient heart block
 - Adults > 40 years of age
 - Increased risk of atrial arrhythmias
 - Atrial fibrillation or flutter
 - Due to atrial dilation
 - Hypothesized risk of thrombus formation
 - Major complications
 - May require surgical intervention
 - Embolization
 - Pericardial tamponade
 - Malposition of device
 - Long-term complications
 - Rare
 - Erosion of atrial roof and aortic root
 - Symptoms: chest pain, hemodynamic instability, cardiac arrest, sudden death
- Long term results
 - Surgical closure of secundum defects excellent
 - For patients operated on < 25 years of age
 - Actuarial survival curve indistinguishable from general population
 - Near-zero mortality for isolated defects
 - Device closure of secundum defects similar to surgical results

References

Anderson, R., Baker, E., Penny, D., Redington, A., Rigby, M., Wernovsky, G. (2010). *Paediatric Cardiology* (3rd ed). Philadelphia, PA: Elsevier.

- Bialkowski, J., Kawot, B., Szkutnik, M., Banaszak, P., Kusa, J., & Skaleski, J. (2004). Closure of atrial septal defects in children. Surgery versus Amplatzer device implantation. *Tex Heart Inst J*, 31, 220-3.
- Chubb, H., Whitaker, J., Williams S. E., Head, C. E., Chung, N. A., Wright, M. J., O'Neill, M. (2014). Pathophysiology and management of arrhythmias associated with atrial septal defect and patent foramen ovale. *Arrhythmia and Electrophysiology Review*, 3(3), 168-172.
- Dipchand, A., & Freidman, J. (2009). *The Hospital for Sick Children. Handbook of Pediatrics* (11th ed). Philadelphia, PA: Saunders, Elsevier.
- Everett A., & Lim S. (2010). *Illustrated Field Guide to Congenital Heart Disease and Repair*. Charlottesville, VA: Scientific Software Solutions.
- Geva, T., Martins , J.D., Wald, R.M. (2014) Atrial septal defects. *Lancet*, 383(9932), 1921-32. PMID: 24725467.
- Ghosh, S., Chatterjee, S., Black, E., Firmin, R. K. (2002). Surgical closure of atrial septal defects in adults: effect of age at operation on outcome. *Heart*, 88(5), 485–487.
- Hazinski, M. F. (2012). *Nursing Care of the Critically Ill Child*. Philadelphia, PA: Elsevier.
- Kaza, A.K., Colan, S.D., Jagers , J., Lu, M., Atz , A.M., Sleeper, L.A., et al. (2011). Surgical Interventions for atrioventricular septal defect subtypes: the pediatric heart network experience. *The Annals of Thoracic Surgery*.
- Kazmouz, S., Kenny D., Cao, Q., Kavinsky, C., Hijazi, Z. (2013). Transcatheter closure of secundum atrial septal defects. *J Invasive Cardiol*, 25(5), 257-264.
- Khonsari, S., & Sintek, C. (2008). *Cardiac Surgery: Safeguards and Pitfalls in Operative Technique*. Philadelphia, PA: Lippincott Williams and Wilkins.
- Park, M. K. (2016). *The Pediatric Cardiology Handbook* (5th ed). Philadelphia, PA: Elsevier Saunders.
- Petit, C. J., Justino, H., Pignatelli, R. H., Crystal, M. A., Payne, W. A., Ing, F. F. (2013). Percutaneous atrial septal defect closure in infants and toddlers: predictors of success. *Pediatric Cardiology*, 34(2), 220-225.
- Slota, M. C. (Ed.). (2006). *Core Curriculum for Pediatric Critical Care Nursing*. Philadelphia, PA: WB Saunders Company.
- Webb, G., & Gatzoulis, M. A. (2006). Congenital Heart Disease for the Adult Cardiologist; Atrial Septal Defects in the Adult. *Circulation*, 114, 1645-1653.
- Vick, G., Bezold, L., Treidman, J., Armsby. (2015). Classification of atrial septal defects (ASD's) and clinical features and diagnosis of isolated ASD's in children. *Up to Date*.

Illustrations reprinted from PedHeart Resource. www.HeartPassport.com. © Scientific Software Solutions, 2016. All rights reserved.

2016